



Dissolvable Antibiotic Beads in Treatment of Periprosthetic Joint Infection and Revision Arthroplasty

The Use of Synthetic Pure Calcium Sulfate (Stimulan®) Impregnated with Vancomycin & Tobramycin

Edward J. McPherson, MD, FACS[†] • Matthew V. Dipane, BA[†] • Sherif M. Sherif, MD[†]

Abstract:

This study reviews the clinical results using commercially pure, synthetic antibiotic-loaded Calcium Sulfate dissolvable beads (Stimulan, Biocomposites, Ltd., Keele, UK) in 250 cases of aseptic and septic revision total hip and total knee arthroplasty. A set protocol of Vancomycin and Tobramycin antibiotic was used in all cases. The rate of wound drainage in this series was 3.2%. Wound drainage was generally seen in cases using higher bead volumes. The incidence of heterotopic bone formation was 1.2%. There were nine failures in this study, six of which were due to infection. We feel that commercially pure, synthetic antibiotic-loaded dissolvable beads are an acceptable delivery tool for local antibiotic delivery in aseptic and septic revision joint arthroplasty of the hip and knee. Further studies are needed to examine the potential of improving outcomes of periprosthetic joint infection with this particular local antibiotic delivery system.

Key words: *Stimulan, Calcium Sulfate, Antibiotic Beads, Periprosthetic Infection, Revision Arthroplasty.*

Level of Evidence: *AAOS Therapeutic Study Level IV.*

Introduction

Periprosthetic joint infection (PJI) is a devastating complication that is potentially a limb and life threatening condition.^{18,19} The extent of the infection is related to many factors including the health of the host patient, the condition of the local soft tissues, and the length of time the infection has been present within the joint. Treatment of periprosthetic infection currently follows established algorithms that have proven successful.²⁶ Treatment depends upon the presence of the bacterial biofilm which envelops the joint prosthesis and adjacent bone. In an acute infection, the biofilm is not established. Treatment is focused on preservation of the implant,

with radical debridement surgery, modular bearing exchange, copious lavage, and perioperative antibiotic therapy. When a biofilm is present, the infection is considered chronic. In this scenario, the biofilm prevents eradication of bacteria and thus implants must be removed along with a radical debridement of bone and soft tissue. Resection of implants most commonly is performed in a two stage protocol. At some centers that focus on PJI, single stage protocols are utilized. With either

[†] LA Orthopedic Institute, Los Angeles, CA
www.laoi.org

protocol, success is particularly dependent upon the quality of joint debridement.^{42,43,47}

Antibiotic therapy in the surgical treatment of a PJI is an important adjuvant therapy. Antibiotic penetration into the local infected area can be problematic. Specifically, local devascularization of infected tissues can prevent local antibiotic delivery. Additionally, any residual biofilm can shield the area from antibiotics.⁴ Local delivery systems offer a solution to this problem. Antibiotic impregnated cement spacers are a useful tool, although a majority of the antibiotic placed into the cement does not elute into the host environment.²³ Non-dissolvable antibiotic polymethylmethacrylate (PMMA) beads can provide higher antibiotic concentrations, but fabrication is tedious. Additionally, it is often difficult to locate and remove all beads at reconstruction.

A local delivery system with dissolvable Calcium Sulfate has been developed to assist in the targeted delivery of antibiotics into the host joint.^{5,6,10} Stimulan (Biocomposites Ltd., Keele, UK) is a synthetic hemihydrate form of Calcium Sulfate. It is produced using a synthetic process resulting in 100% purity with no traces of potentially toxic impurities which has been associated with naturally occurring mineral sources of Calcium Sulfate.^{3,22} It is biocompatible, composed of hydrophilic crystals, soft after hydration, and disappears on X-rays after two to three weeks when placed within a joint compartment.

Stimulan also has the advantage of delivering a wider spectrum of antibiotic combinations into the joint. It cures at a low temperature, thus allowing heat-sensitive antibiotics to be mixed with Stimulan. This is in contrast to PMMA in which only heat-stable antibiotics can be used. Even with these advantages, there has been concern with using dissolvable antibiotic-loaded Calcium Sulfate.^{3,22} The main concern has been with postoperative wound drainage. Prior to Stimulan, dissolvable Calcium Sulfate products were derived from gypsum, a natural product mined and processed into Calcium Sulfate. The processing of gypsum creates a product that has a relatively low pH and contains residual by-products that may illicit an inflammatory reaction when the product is placed into a joint wound. The inflammatory reaction in

turn impedes wound healing and causes a wound to drain.^{22,40}

The purpose of this study is to examine the initial review of the use of commercially pure, synthetic antibiotic-loaded dissolvable Calcium Sulfate beads (Stimulan) in their application in treating two groups of patients. One group contains patients with periprosthetic infection. The other contains patients undergoing revision joint arthroplasty. Historically this latter group has a higher known risk of periprosthetic infection.^{11,14,15,39,43,47} We review outcomes and complications and compare our findings to previous studies employing processed calcium sulfate derived from gypsum product. To our knowledge, this is the first study reporting on the use of commercially pure, synthetic antibiotic-loaded Calcium Sulfate in the treatment of two such groups.

Materials & Methods

Between January 2010 and September 2012, 342 revision THA and TKA procedures were performed. This included aseptic revisions, two stage septic revisions, and one stage DECRA (Debridement, modular Exchange, Component Retention, IV Antibiotic) procedures for acute PJI. During this time we used dissolvable antibiotic beads in 250 of these cases. The antibiotic combination used in this series was a preset protocol consisting of one (1) gram of Vancomycin powder and 240mg of liquid Tobramycin mixed with 10cc of Stimulan powder (see technique below). For two-stage procedures for infected TKA and THA, Stimulan antibiotic beads were inserted both at the time of resection arthroplasty and reimplantation.

Preoperatively, all patients were staged for periprosthetic infection risk according to the Musculoskeletal Infection Society – Americas (MSIS-A) staging system.²⁶ The integrity of each patient's immune defense system was assessed and all compromising factors were documented.^{26,27,8} Aseptic revisions in the MSIS-A classification were considered a Stage Zero. All revision procedures were preoperatively aspirated by the surgeon (ejm) with cell count and culture analysis. Pre-operative Westergren Sedimentation Rates and Quantitative CRP were also obtained on all patients. Clinical scoring was performed on all patients including

Harris Hip and Oxford scores for hips and Knee Society and Oxford scores for knees. Perioperative and post-operative complications were recorded. Radiographs were obtained at 3 months and 1 year post-operatively.

At the time of knee resection arthroplasty, the knee was stabilized with an articulated antibiotic-loaded PMMA spacer. When the knee was unstable, the leg was stabilized with an antibiotic-loaded PMMA endofusion device with medullary rods inserted into the femur and tibia. Cobalt cement (Biomet, Warsaw, IN) was used in resection and reimplantation/revision procedures. For resections, 5 grams of Vancomycin powder and 3.6 grams of Tobramycin powder were mixed into each 40 gram bag of Cobalt cement. Typically 3-5 bags of cement were used at resection. For revision or reimplantation procedures, 2-3 bags of

Cobalt cement were typically used. One gram of Vancomycin powder was placed in each 40 gram bag of cement.

For knee cases, the Stimulan beads were delivered along the medial and lateral gutters of the knee, just before closure. A 10 french silicone Blake drain (Ethicon, Inc., San Angelo, TX) was placed along the lateral gutter and the arthrotomy closed in midflexion over a bump. No beads were placed in the subcutaneous layer. Superficial subcutaneous drains were placed as indicated. The deep drain was always removed between 24 and 36 hours. The superficial drain(s) was removed between 48 and 72 hours. In the two stage septic revision group, a compressive Robert-Jones dressing was placed on the leg for 5-7 days, both at resection and reimplantation. Figures 1 and 2 (see Appendices) demonstrate surgical technique and placement of the Stimulan beads.

Figures 1a - 1e: Radiographs of 65-year-old male who underwent a two-stage revision protocol for a chronic periprosthetic infection of his left TKA. The patient suffers from diabetes.

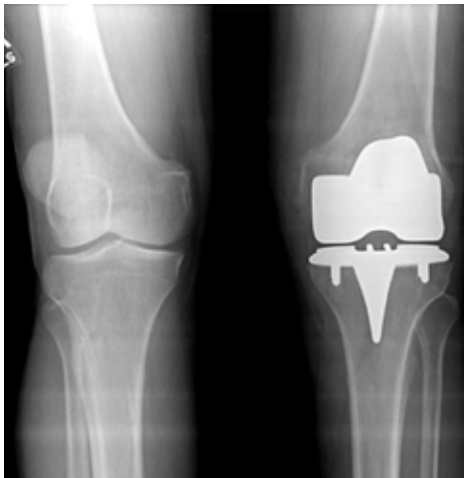


Figure 1a: Preoperative standing AP radiograph of left TKA. Aspiration cultures grew *Staphylococcus warneri* and *Stenotrophomonas maltophilia*.

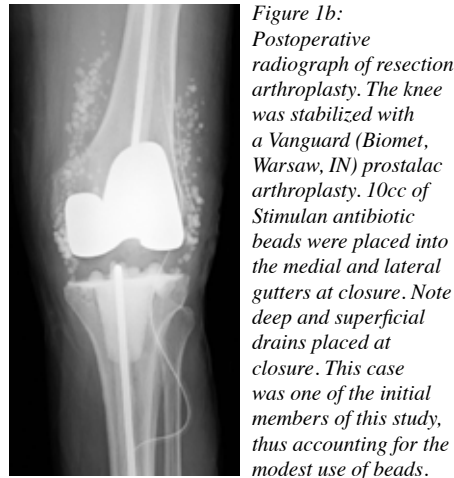


Figure 1b: Postoperative radiograph of resection arthroplasty. The knee was stabilized with a Vanguard (Biomet, Warsaw, IN) prostatic arthroplasty. 10cc of Stimulan antibiotic beads were placed into the medial and lateral gutters at closure. Note deep and superficial drains placed at closure. This case was one of the initial members of this study, thus accounting for the modest use of beads.

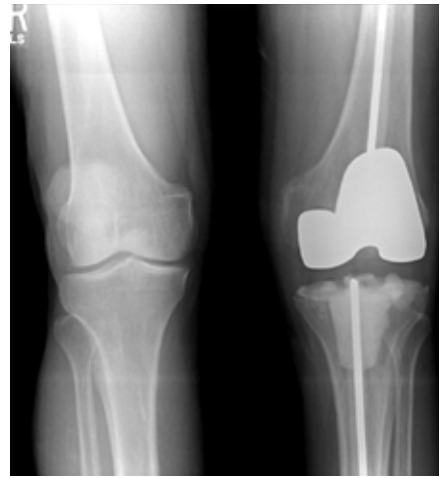

Figure 1c: Preoperative AP radiograph of knees prior to reimplantation. This radiograph was taken 9 weeks after resection arthroplasty. All Calcium Sulfate beads have dissolved. Preoperative aspiration of the knee was negative.

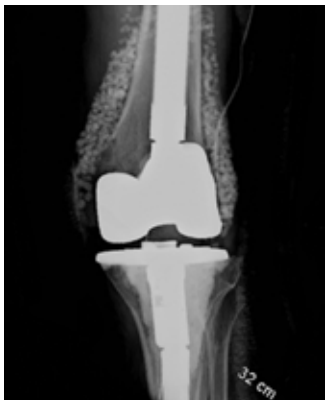

Figure 1d: Postoperative AP radiograph at reimplantation surgery. The knee was reconstructed using the Vanguard revision knee system (Biomet, Warsaw, IN). At closure 20cc of Stimulan antibiotic beads were placed into the knee joint. Again note deep drain placed into knee.

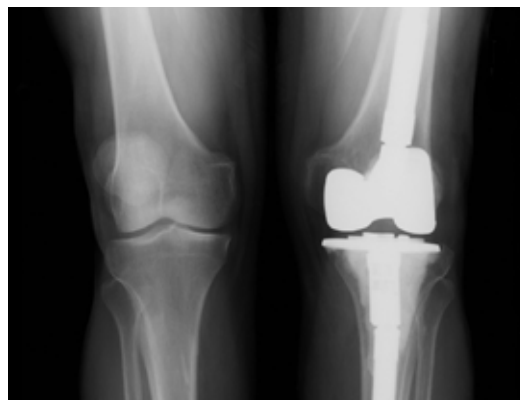

Figure 1e: Standing AP radiograph taken 18 months after reimplantation surgery. All Calcium Sulfate beads have dissolved. The patient remains infection free with knee range of 0-125 degrees.

Figures 2a – 2d: Radiographs of a 57-year-old male who underwent a single-stage revision protocol for Nickel hypersensitivity and clinical pain of his left TKA.

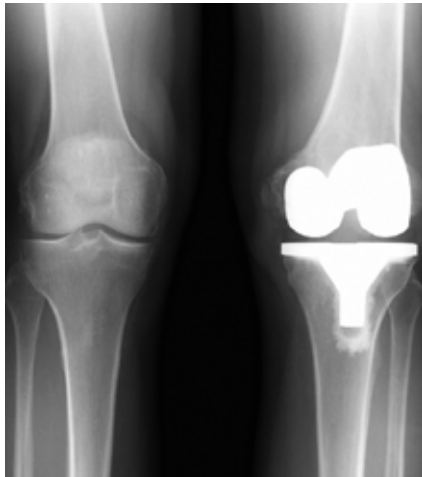


Figure 2a: Preoperative standing AP radiograph. Note well-fixed TKA implants. The patient had knee range of 0-130 degrees, but had a persistently large knee effusion and chronic pain.

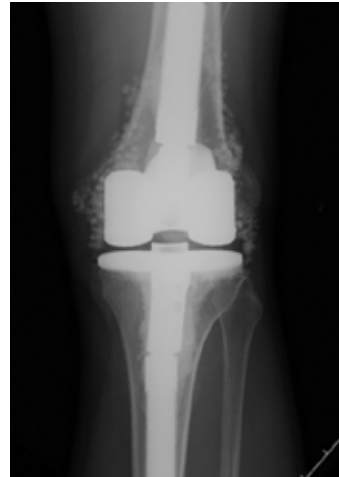

Figure 2b: Postoperative AP radiograph of revision TKA. 10cc of Stimulan antibiotic beads were placed into the medial and lateral gutters of the knee. Note drain placed into knee joint at closure.

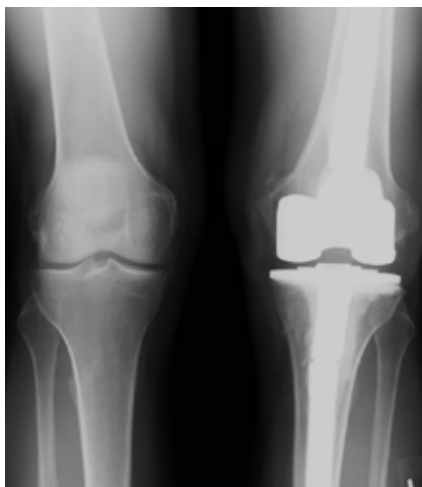

Figure 2c: Postoperative standing AP radiograph taken 2 months after revision surgery. All Calcium Sulfate beads have dissolved. Also note that the knee effusion has abated.

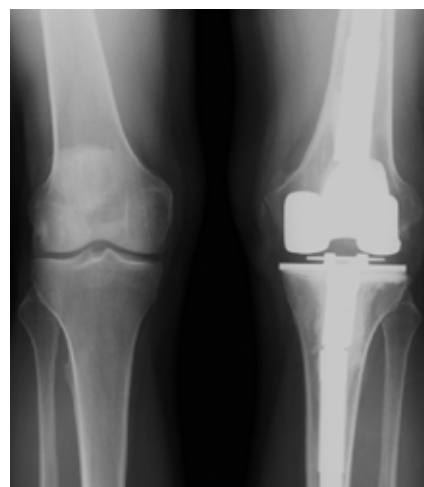

Figure 2d: Postoperative standing AP radiograph taken 8 months after revision surgery. The knee has regained knee range of 0-135 degrees. Knee effusion remains minimal.

At the time of hip resection, the hip was stabilized with an articulated antibiotic-loaded PMMA hip spacer. The Modular Stage One hip spacer system was used (Biomet, Warsaw, IN). When segmental deficiencies were present in the acetabulum, an antibiotic-loaded PMMA spacer was formed in-situ in the pelvis/acetabulum using a large monopolar head trial as a mold. The cement was secured with two to four 6.5mm titanium cancellous screws placed partly into bone to serve as rebar posts; this prevented spacer displacement. The screws were covered entirely with cement (screwdriver holes were filled with bone wax to allow removal at reconstruction). Cobalt cement was used at resection arthroplasty with the same antibiotic combination as the knee. For revision or reimplantation procedures almost all cases were implanted with cementless reconstruction systems. When a reconstruction cage was used for acetabular

reconstruction, the acetabular socket was cemented into the cage with Cobalt cement. One gram of Vancomycin powder was mixed into each 40 gram bag of cement.

For hip cases, the Stimulan antibiotics beads were delivered into the deep hip space inferior to the acetabulum and around the proximal femur. A 10 french Blake Drain was placed just under the Tensor Fascia layer. Additional subcutaneous drains were placed as indicated. No beads were placed in the subcutaneous layer. The Tensor Fascia drain was always removed between 24 and 36 hours. The superficial drains were pulled between 48 and 72 hours. In the two stage septic revision group, a spica brace (set between 20-70 degrees) was used both at explantation (until reimplantation) and reimplantation (4-6 weeks). Figures 3 and 4 (see Appendices) demonstrate surgical technique and placement of Stimulan beads.

Figures 3a – 3c: Radiographs of a 72-year-old male who underwent a single-stage revision protocol for prosthetic femoral-acetabular impingement and clinical pain of his right THA.

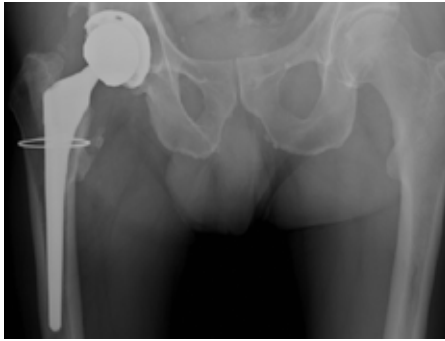


Figure 3a: Preoperative AP radiograph of pelvis. Note small amount of heterotopic bone near lateral acetabulum and lesser trochanter.

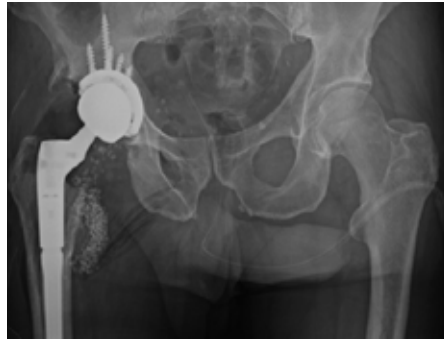


Figure 3b: Postoperative AP radiograph of revision THA. 10cc of Stimulan antibiotic beads were placed within the hip joint, mainly inferiorly. The beads gravitated to this region as this area was dissected to remove the heterotopic bone and scar tissue from the proximal femur.

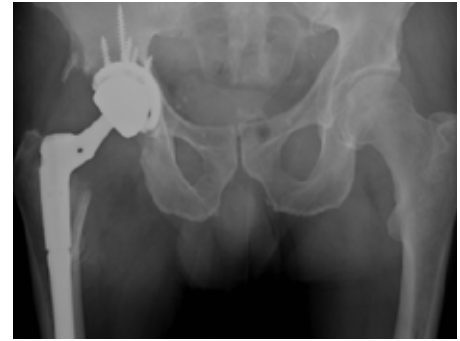

Figure 3c: Postoperative AP radiograph taken 3 months after revision surgery. All Calcium Sulfate beads have dissolved. Note no new heterotopic bone has formed. This patient did not receive any perioperative treatment to prevent heterotopic bone formation (i.e., no radiation or Indocin).

Figures 4a – 4f: Radiographs of a 64-year-old male who underwent a two-stage revision protocol for a chronic periprosthetic infection of his right THA. The patient suffers from hypertrophic osteoarthritis and DISH.

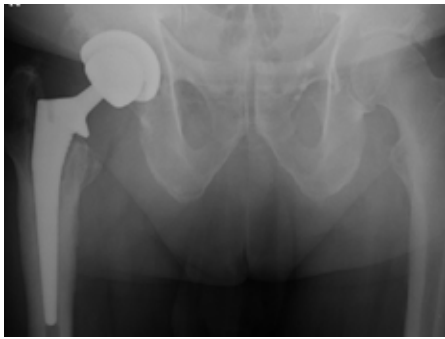


Figure 4a: Preoperative AP radiograph of pelvis showing infected right THA. Preoperative aspiration grew *Staphylococcus epidermidis*. Note endosteal resorption of bone around proximal femoral stem.

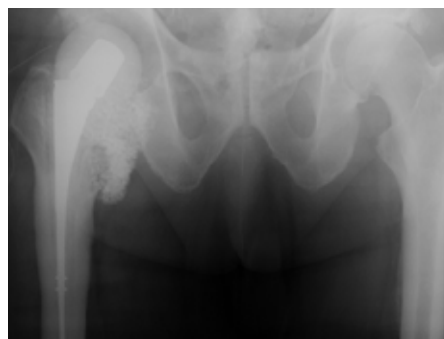

Figure 4b: Postoperative radiograph of resection arthroplasty. The hip was stabilized with a Modular Stage One (Biomet, Warsaw, IN) antibiotic loaded methyl methacrylate articulated spacer. 40cc of Stimulan antibiotic beads were placed into the hip joint. Note drain that was placed underneath the tensor fascia layer at closure.

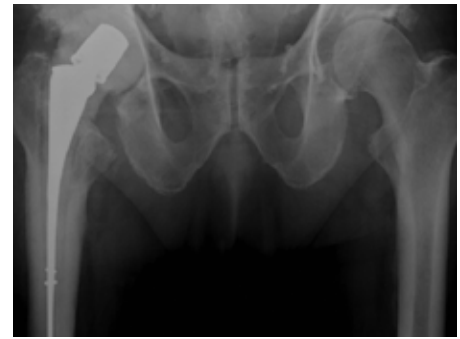

Figure 4c: Preoperative AP radiograph of pelvis prior to reimplantation surgery. This radiograph was taken 8 weeks after resection arthroplasty. All Calcium Sulfate beads have dissolved. Preoperative aspiration of the hip was negative.

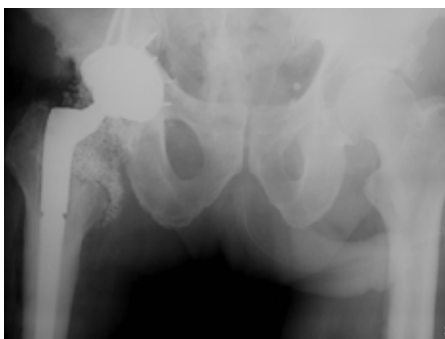

Figure 4d: Postoperative AP radiograph of pelvis at reimplantation surgery. The acetabulum was reconstructed with a porous cup cage (Signature Orthopaedics, Chatsville, AU) with screws. A Magnum cup (Biomet, Warsaw, IN) was cemented into the cup cage. A dual articulating bearing was utilized (Biomet, Warsaw, IN). The femur was reimplanted with an Arcos modular stem (Biomet, Warsaw, IN). At closure, 40cc of Stimulan antibiotic beads were placed into the hip joint.

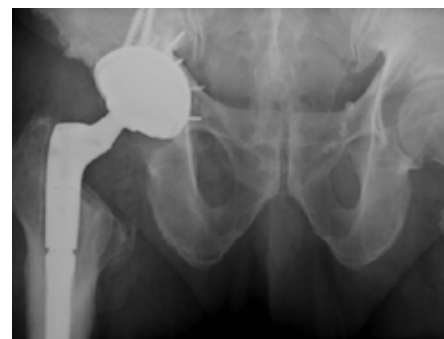

Figure 4e: AP radiograph of pelvis taken 5 weeks after reimplantation surgery. All Calcium Sulfate beads have dissolved. Implants show stable initial fixation.

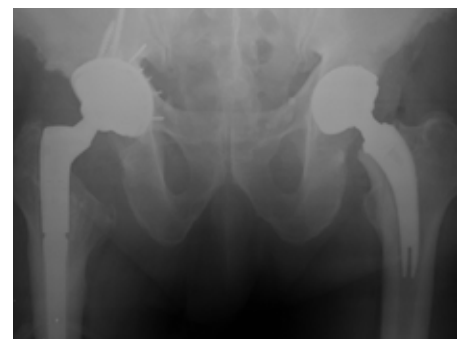

Figure 4f: AP radiograph of pelvis taken 3.5 months after reimplantation surgery. No heterotopic bone has formed. Implants maintain initial biologic integration.

Antibiotic Bead Preparation

This study utilized commercially pure, synthetic neutral pH balanced Calcium Sulfate (Stimulan). The rapid cure kit was used which includes 10cc (20gm) of Calcium Sulfate, 2 pre-measured mixing solution bulbs, 1 syringe, 1 pellet mold, and 1 spatula. The mold produces three different sizes for the beads (3, 4.8, and 6mm) as demonstrated in Figure 5 (See Appendices).

For this study, one gram of Vancomycin powder is added to 10cc (20gm) of Calcium Sulfate and the two powders are well mixed. The mixture is then added to 240mg (40mg/cc) of liquid Tobramycin in a plastic mixing bowl provided in the kit. Ingredients are mixed for 30 seconds until “doughy.” The paste is then applied with a spatula into a silicone bead mold and left to set for 10 to 15 minutes with a typical OR room temperature of 60-62° fahrenheit.^{20,21,22} Once set, the beads are harvested and kept in a sterile container until used.

All patients were followed up for a minimum of 3 months. Failure was recognized as the need for component removal for any reason. Monitoring for infection included clinical exam with C-reactive protein tests at 3 months, 6 months, and one year post-operatively. A suspicion of infection prompted a joint aspiration. For patients undergoing reimplantation procedures, a pre-operative negative culture from joint aspiration was mandatory.

Results

The volume of Stimulan antibiotic-loaded beads used for each procedure ranged from 5cc to 70cc in hip cases and 5cc to 50cc in knee cases. As early cases showed no significant clinical problems, the volume of Stimulan beads was gradually increased. The upper limit of bead volume was dependant upon the ability to close the deep soft tissue envelope with a tension free closure. The



Figure 5: Photograph showing Stimulan Bead Set. The blue plate is a sterile, silicone mat that can make 3 different sized beads (3, 4.8, and 6mm). In this series we primarily used 3 and 4.8mm beads to increase overall surface area and allow for faster dissolution of Calcium Sulfate. The beads shown here are from a 10cc batch of Stimulan. The smaller beads are 3mm diameter beads. The larger beads are 4.8mm diameter beads.

average volume was different for each of the four different categories and all are listed in Table 1 (see Appendices).

The incidence of wound drainage in this study was relatively low considering the overall complexity of the cases. There were eight cases (3.2%) of post-operative wound drainage requiring intervention. Intervention included lavage and debridement, wound vac placement, and/or application of a compressive dressing on the wound. When the surgical wound began to drain, the post-operative thromboembolic prophylaxis regimen was modified, usually by using mechanical foot pumps, until wound drainage resolved. At the time of debridement surgery, the old Stimulan beads were removed and new beads were inserted into the wound. There were five cases (3.5%) of knee wound drainage, with two cases requiring surgical wound lavage and debridement. There were three cases (2.8%) of hip wound drainage, with two cases requiring surgical wound lavage and debridement.

Heterotopic bone formation was identified in three cases (1.2%). Heterotopic bone formation occurred in one knee case (resection arthroplasty with static spacer) and two hip cases (one resection arthroplasty and one reimplantation procedure).

Heterotopic ossification was seen generally when a large volume of Stimulan was used (average 33cc per case). In all cases, the heterotopic bone was considered mild, rated Brooker I-II class. The character of the heterotopic bone in the two cases that were re-operated (for reimplantation) was considered thin and “wispy.” It was easily removed from the surrounding tissues. In review of the post-operative radiographs, the heterotopic bone formed in areas where the Stimulan beads were densely packed.

In two-stage hip and knee procedures, we were able to inspect the surgical wounds at reimplantation. The time between resection and reimplantation ranged from 9 to 15 weeks, with an average of 12 weeks. In all cases, there were no observable beads remaining. In twenty percent of the cases we noticed that the synovium was coated with a thin white layer of material that could not be rubbed away. This white material was typically located within the medial and lateral gutters of knee cases and in the infra-acetabular areas of hips. Transection of synovial specimens showed that the white material was only located on the superficial surface of the synovial tissue. The white coating was generally observed when bead volumes of 20cc or more were used.

Out of our 250 procedures there were 29 complications (11 hips and 18 knees) for a complication rate of 11.6%. All complications are listed in Tables 2 & 3 (see Appendices) along with their MSIS-A host grade. A majority of complications occurred in patients with a grade B or C (MSIS-A) medical host. Eight of the 29 complications had wound related complications (3 hips and 5 knees). There were nine failures (3.6%) in this study. All failures are listed in Tables 4 & 5 along with their medical host grade. Six failures were a result of infection. Excluding the above infection failures, all remaining patients had a normal C-reactive protein when tested between 6 and 12 months post-operatively.

Discussion

In this series we used Stimulan as a vehicle to deliver a localized dose of antibiotics to an area at risk for infection (i.e. operative wound). This is a preliminary study to gauge the effectiveness

of utilizing this particular carrier in septic and aseptic revision joint arthroplasty of the hip and knee. The strategy of using a localized antibiotic delivery system is that it avoids the potential toxicity of intravenous antibiotics. The side effects of even short courses of IV antibiotics are well documented.¹ Localized delivery via Stimulan into a joint replacement has already been shown to deliver antibiotics up to 50 times greater than MIC levels for many pathogenic bacteria found in orthopaedic infections.^{15,16,23,24,33} A local antibiotic delivery system is appealing, as it offers a high local concentration of the antibiotics with low serum levels. In contrast, antibiotic-loaded bone cement (PMMA) has historically been an alternative system used for local antibiotic delivery, but there are problems with this method. Firstly, the antibiotic is released by surface bleaching, not elution. This results in relatively low local drug concentrations.²³ There is also the need for a second surgery to remove the cement beads in single stage procedures. Furthermore, only heat stable antibiotics can be utilized with PMMA. Biodegradable delivery systems are more attractive because they provide solutions for these issues encountered with the PMMA method of antibiotic delivery.^{1,2,9,13,28,31,32,46}

Calcium Sulfate has been employed as a bone void filler for a long time and its popularity as a local antibiotic delivery system is growing in the treatment of musculoskeletal infections.^{7,12,17,29,34,36,37,38} Antibiotic-loaded dissolvable Calcium Sulfate beads have previously been used in clinical trials, but the results have not been favorable. Among the main problems encountered are post-operative wound drainage and a toxic reactive synovitis that occurs when beads are placed within a joint. Wound complication rates were reported to be between 25-30% with several explanations existing for such regular occurrence.^{22,3,30,40} The predominant thinking attributes the cause of wound drainage to the purification processes of “traditional” Calcium Sulfate products. Prior to Stimulan, all Calcium Sulfate products were derived from gypsum harvested from the earth. Various proprietary filtering and wash processes were developed to produce medical grade Calcium Sulfate products. Despite arduous attempts to derive pure Calcium Sulfate products, however, impurities still exist.^{22,35} Additionally, the chemicals used to wash the

gypsum product still remain within the Calcium Sulfate. The result is that the product, once delivered into the human body, is non-physiologic and potentially inflammatory when exposed to the synovial fluid environment. In contrast, Stimulan is derived from commercially pure, synthetic Calcium Sulfate which is blended via a proprietary process to create a product that is considered less “harsh” to the synovial joint environment. It was for this reason that this study was undertaken.

In our study, the incidence of wound drainage in revision joint arthroplasty was found to be low. Overall 3.2% of cases experienced wound drainage. A majority of the 8 occurrences were found in medically compromised hosts (MSIS-A Grade B or C hosts). Furthermore, wound drainage tended to present in cases where the volume of beads used was ≥ 30 cc. There are several possible explanations for this occurrence. One explanation is that the large volume of beads caused excessive mechanical stretching of the deep soft tissue envelope with joint range, causing the wound to leak. Another possibility is a chemical effect, as large volumes of beads could potentially cause a hyperosmotic effect resulting in joint distension and wound leakage. A third possible factor is the quality of the local tissues and the health of the patient. In the revision scenario, soft tissues are often attenuated from previous surgery and mechanical damage to the local tissues is commonly encountered. This, combined with poor systemic health (e.g. diabetes, smoking, prednisone treatment), leads to wound drainage. We believe that wound drainage can be mitigated by employing modest bead volumes (<30cc) combined with surgical techniques which encourage a water-tight deep soft tissue envelope.

Heterotopic ossification is another potential concern with the use of Calcium Sulfate as a dissolvable pellet. Calcium Sulfate, when used in the intra-osseous environment, is an osteoconductive agent. Its application as a bone void filler is well established.^{25,41,44,45} When it is placed within the intra-articular environment, the beads are dissolved within the synovial fluid and eventually resorbed. However, if there is a reduced synovial fluid environment (i.e. arthrofibrosis) and exposed intra-articular bone (from periosteal stripping during surgery) the Calcium Sulfate may have sufficient osteoconductive influence to form new periarticular

bone. This is especially so when endoprosthetic hinge devices about the knee are used. Our overall incidence of heterotopic bone in this series was 1.2%. The type of heterotopic bone tended to be thin and laminate. In most cases the heterotopic bone did not dramatically affect joint function. In cases of resection arthroplasty where heterotopic bone formed, it was easily removed at the time of reimplantation. We feel that heterotopic bone formation is not a major prohibitive complication for using commercially pure, synthetic antibiotic-loaded Calcium Sulfate dissolvable beads.

A potential drawback to using Calcium Sulfate in revision joint arthroplasty is the potential for mechanical abrasion of the prosthetic articular surfaces. The beads within the joint envelope can migrate and get in between the articular surfaces. With weight bearing, the beads can get crushed and can potentially cause scratching of the articular surfaces. Current work is ongoing in 6 retrieval Prostalac spacers to look at the articular surfaces for pitting and scratching (Clarke I, McPherson EJ, Peterson Tribology Laboratory, Loma Linda, CA). Maale et al reported using Stimulan beads loaded with Vancomycin and Tobramycin in single-stage septic revision total knee arthroplasty. They found that the Stimulan beads were soft after hydration and do not scratch the joint surface.^{23,24} Even if Calcium Sulfate beads did create scratches or polyethylene pitting, their use for localized antibiotic delivery in periprosthetic infection or total joints at risk for infection still may be preferable. Their use will depend on a case by case risk assessment. Long term clinical follow-up is needed to answer this question more definitively.

In summary, we find the use of commercially pure, synthetic antibiotic-loaded Calcium Sulfate is an acceptable adjuvant treatment tool in revision total hip and total knee arthroplasty. We noted low rates of postoperative wound drainage and heterotopic bone formation. In contrast, prior Calcium Sulfate products derived from processed gypsum have shown significant problems with wound healing and wound drainage.^{1,2} The Stimulan-antibiotic construct is adaptable, whereby various antibiotic formulas can be utilized.³ Furthermore, this localized antibiotic delivery method is relatively inexpensive and obviates the need for a second surgery (i.e. removal of PMMA antibiotic beads).

Initial observations with Stimulan antibiotic beads are encouraging. We will continue to explore and research the efficacy of antibiotic-loaded Stimulan beads. Our next phase is to measure local antibiotic concentrations in-vivo in revision joint arthroplasty. We strive to document and corroborate prior findings by Maale and Eager who showed high local antibiotic concentrations within prosthetic knee cases. Additionally, we will continue to review the mechanical effects that Calcium Sulfate beads have upon the articular surfaces of prosthetic implants. Finally, we would like to conduct a study to examine the potential of improving the results of PJI with Stimulan beads via randomized multicenter trials.

Table 1 - Results

Aseptic Revision TKA		Aseptic Revision THA	
N=66		N=58	
Avg Stimulan/case	16cc	Avg Stimulan/case	20cc
Complications	6	Complications	4
Failures	2	Failures	2
Deceased	1	Deceased	1
Drainage	1	Drainage	2
DECRA TKA		DECRA THA	
N=16		N=8	
Avg Stimulan/case	21cc	Avg Stimulan/case	35cc
Complications	1	Complications	1
Failures	2	Failures	1
Deceased	0	Deceased	2
Drainage	0	Drainage	1
Resection TKA		Resection THA	
N=35		N=24	
Avg Stimulan/case	27cc	Avg Stimulan/case	33cc
Complications	7	Complications	4
Failures	0	Failures	1
Deceased	0	Deceased	0
Drainage	2	Drainage	0
Reimplantation TKA		Reimplantation THA	
N=25		N=18	
Avg Stimulan/case	24cc	Avg Stimulan/case	34cc
Complications	4	Complications	2
Failures	0	Failures	1
Deceased	0	Deceased	0
Drainage	2	Drainage	0

Table 2 – Knee Complications

Procedure	Case #	Volume	MSIS-A Host Grade	Complication
Aseptic Knee Revisions	Knee 1	10 cc	B	Dynamic rotational instability with buckling.
	Knee 2	10 cc	B	Wound drainage, cellulitis, periprosthetic infection with wound drainage. I&D with modular bearing exchange. No infection at 2-year follow-up.
	Knee 3	10cc	C	Acute knee infection from dental abscess. Failed DECRA. Implants resected 5 months post-op.
	Knee 4	10cc	A	Arthrofibrosis – knee manipulation.
	Knee 5	20cc	A	Extensor lag.
	Knee 6	10cc	A	Fall with traumatic arthromy. I&D and reclosure. No infection at 1-year follow-up.
Aseptic Knee Revisions	Knee 1	10 cc	B	Dynamic rotational instability with buckling.
Aseptic Knee Revisions	Knee 1	10 cc	B	Dynamic rotational instability with buckling.
	Knee 9	20cc	B	Heterotopic bone formation in medial and lateral gutters. Removed at reimplantation.
	Knee 10	50cc	A	Secondary infection with Candida Albicans. Repeat debridement and spacer exchange.
	Knee 11	30cc	A	Wound drainage. Wound vac applied. Drainage resolved.
	Knee 12	30cc	B	Superficial wound dehiscence with drainage. Wound revised and closed.
	Knee 13	40cc	B	Acute renal failure, Creatinine 3.6. No dialysis.
	Knee 14	30cc	B	Acute on chronic renal failure. Dialysis for 3 weeks. Resolved to baseline.
Aseptic Knee Revisions	Knee 1	10 cc	B	Dynamic rotational instability with buckling.
	Knee 16	20cc	C	Wound drainage, I&D. Recurrent infection. AKA.
	Knee 17	30cc	C	Wound drainage at 2 weeks post-op. I&D with lavage. Stable.
	Knee 18	10cc	B	Partial small bowel obstruction. Readmitted at 3 weeks post-op for 5 days. No surgery required.

Table 3 – Hip Complications

<i>Procedure</i>	<i>Case #</i>	<i>Volume</i>	<i>MSIS-A Host Grade</i>	<i>Complication</i>
Aseptic Hip Revisions	Hip 1	10cc	B	Wound drainage at 3 weeks post-op. I&D with additional antibiotics beads. Wound infection at 2 months post-op. I&D with antibiotics beads. Stable at 1 year.
	Hip 2	30cc	B	Implant Bow Mismatch. Distal Femoral crack. No additional surgery.
	Hip 3	10cc	B	Hematoma with drainage. I&D with evacuation of the hematoma at 2 weeks post-op.
	Hip 4	10cc	B	Infection. I&D at 4 weeks post-op. Negative aspiration culture at 6 months post-op.
Hip DECRA's	Hip 5	40cc	B	Wound drainage post-op. Malnutrition, albumin 2.1. Recurrent infection at 3 months. Hip Resected at 6 months.
Hip Resections	Hip 6	40cc	A	DVT Rt. Arm from PICC line at 6 weeks post-op. Coumadin therapy.
	Hip 7	40cc	A	Heterotopic bone formation. Removed at reimplantation.
	Hip 8	40cc	B	Heterotopic bone formation. Removed at reimplantation.
	Hip 9	20cc	B	Intra-operative hypotension, sepsis.
Hip Reimplants	Hip 10	40cc	B	Recurrent dislocation. Revision to constrained socket.
	Hip 11	70cc	B	Wound drainage. Clear serous fluid. Wound Vac applied for 5 days.

Table 4 – Knee Failures

<i>Procedure</i>	<i>Case #</i>	<i>Volume</i>	<i>MSIS-A Host Grade</i>	<i>Reason for failure</i>
Aseptic Knee Revisions	Knee 20	20cc	B	MRSA infection, extensor allograft removal, lavage debridement. Implant infection free at 1 year.
	Knee 21	20cc	A	Infection -Staph A. Implants resected for 2 stage protocol.
Knee DECRA's	Knee 22	30cc	C	Failed DECRA. Recurrent infection. AKA.
	Knee 23	10cc	B	Recurrent patellar subluxation. VMO Advancement procedure at 4 months. Stable at 1 year. No infection.

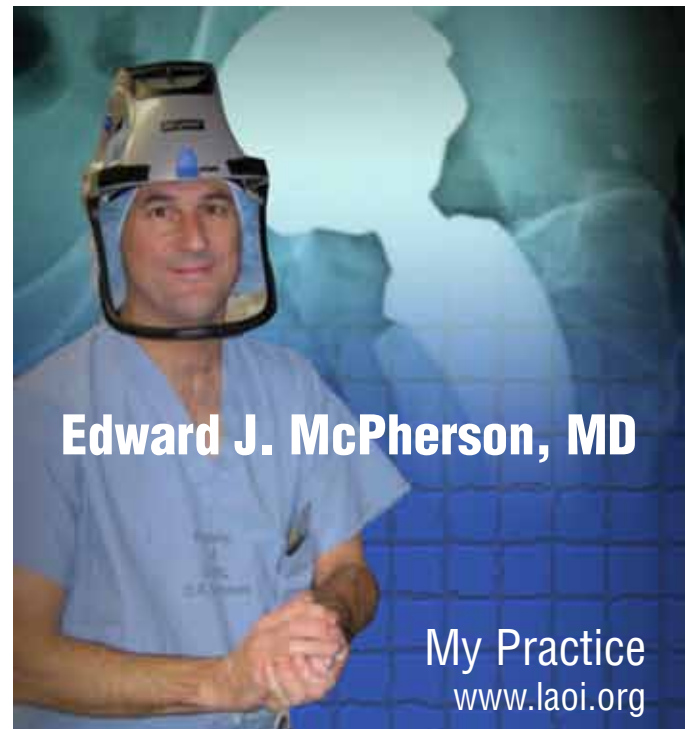
Table 5 – Hip Failures

<i>Procedure</i>	<i>Case #</i>	<i>Volume</i>	<i>MSIS-A Host Grade</i>	<i>Reason for failure</i>
Aseptic Hip Revisions	Hip 12	10cc	A	Aseptic loosening cup. Revision to triflange cage.
	Hip 13	30cc	A	Aseptic loosening cup. Revision to custom triflange cage.
Hip DECRA's	Hip 14	30cc	C	Recurrent infection. Patient died of concomitant bowel perforation.
Hip Resections	Hip 15	30cc	C	New infection hip at 6 months post-operative. Dental infection Strep Viridans. DECRA. Implant stable at 18 months. Normal CRP.
Hip Reimplants	Hip 16	20cc	C	Reinfection at 3 months. DECRA procedure. Patient with CLL. Died from blast crisis 6 months after DECRA procedure.

References

1. Blaha JD, Calhoun JH, Nelson CL, et al. Comparison of the clinical efficacy and tolerance of gentamicin PMMA beads on surgical wire versus combined and systemic therapy for osteomyelitis. *Clinical Orthopaedics and Related Research*. 1993; 295: 8-12.
2. Bowyer GW, Cumberland N. Antibiotic release from impregnated pellets and beads. *The Journal of Trauma*. 1994; 36: 3331-5.
3. Ciemy G. Comparing OsteoSet and Stimulan as antibiotic-loaded, Calcium sulfate beads in the management of musculoskeletal infection. Paper presented at: Annual Open Scientific Meeting of the Musculoskeletal Infection Society 2009. Proceedings of the 19th Meeting of the Musculoskeletal Infection Society; 2009 Aug 7-8; San Diego, California.
4. Costerton JW, Stewart PS, Greenberg EP. Bacterial biofilm: a common cause of persistent infections. *Science*. 1999; 284: 1318-22.
5. Dacquet V, Varlet A, Tandogan RN, et al. Antibiotic-impregnated plaster of Paris beads. Trials with Teicoplanin. *Clinical Orthopaedics and Related Research*. 1992; 282: 241-9.
6. Dahners LE, Funderburk CH. Gentamicin-loaded plaster of Paris as a treatment of experimental osteomyelitis in rabbits. *Clinical Orthopaedics and Related Research*. 1987; 219: 278-82.
7. Damien CJ, Parsons JR. Bone graft and bone graft substitutes: a review of current technology and applications. *Journal of Applied Biomaterials*. 1991; 2(3): 187-203.
8. Enneking WF, Durham W, Gebhardt MC. A system for the functional evaluation of reconstruction procedure after surgical treatment of tumors of the musculoskeletal system. *Clinical Orthopaedics and Related Research*. 1993; 286: 241-6.
9. Evans RP, Nelson CL. Gentamicin-impregnated polymethylmethacrylate beads compared with systemic therapy in the treatment of chronic osteomyelitis. *Clinical Orthopaedics and Related Research*. 1993; 295: 37-42.
10. Evrard J, Kerri O, Martini M, Conort O. Treatment of chronic osteomyelitis by antibiotic loaded plaster of Paris pellets. *Path Biol*. 1990; 38: 5543-7.
11. Garvin KL, Hansen AD. Infection after total hip arthroplasty: past, present, and future. *JBJS Am*. 1995; 77: 1576-1588.
12. Gitelis S, Piasecki P, Turner T, Haggard W, Charters J, Urban R. Use of calcium sulfate-based bone graft substitute for benign bone lesions. *Orthopedics*. 2001; 24(2): 162-166.
13. Henry SL, Hood GA, Seligson D. Long-term implantation of gentamicin-polymethylmethacrylate antibiotic beads. *Clinical Orthopaedics and Related Research*. 1993; 295: 47-53.
14. Hunter GA, Welsh RP, et al. The Results of Revision of Total Hip Arthroplasty. *JBJS*. 1979; 61-B(4): 419-21.
15. Kanellakopoulou K, Galanopoulos I, et al. Treatment of experimental Osteomyelitis caused by methicillin-resistant Staphylococcus aureus with a synthetic carrier of calcium sulphate (Stimulan) releasing moxifloxacin. *International Journal of Antimicrobial Agents*. 2009; 33(4): 354-9.
16. Kanellakopoulou K, Panagopoulos P, Giannitsioti E et al. In vitro elution of Daptomycin by a synthetic crystalline semihydrate form of calcium sulfate, Stimulan. *Antimicrobial Agents and Chemotherapy*. 2009; 53: 3106-3107.
17. Kelly CM, Wilkins RM, Gitelis S, Hartjen C, Watson JT, Kim PT. The use of surgical grade calcium sulfate as a bone graft substitute: results of a multicenter trial. *Clinical Orthopaedics and Related Research*. 2001; 382: 42-50.
18. Kurtz SM, Lau E, Schmier J et al. Infection burden for hip and knee arthroplasty in the United States. *The Journal of Arthroplasty*. 23(7): 984-91.
19. Kurtz SM, Ong KL, Lau E. Prosthetic Joint Infection Risk After TKA in the Medicare Population. *Clinical Orthopaedics and Related Research*. 2010; 468: 52-56.
20. Laycock PA, Brayford MJ, Cooper JJ. A simple acoustic technique to assess the setting time of antibiotic loaded calcium sulphate. Poster presented at eCM XII: Implant Infection. Proceedings of the 12th eCells & Materials Conference; 2011 Jun 22-24; Congress Center, Switzerland.
21. Laycock PA, Brayford MJ, Cooper JJ. Effects of antibiotic addition on the setting time of calcium sulphate bone cement. Poster presented at eCM XII: Implant Infection. Proceedings of the 12th eCells & Materials Conference; 2011 Jun 22-24; Congress Center, Switzerland.
22. Lee GH, Khoury JG, Bell JE. Adverse Reactions To Osteoset Bone Graft Substitute, the Incidence in a consecutive series. *The Iowa Orthopaedic Journal*. 2002; 22: 35-8.
23. Maale GE, Eager JJ. Local elution profiles of a highly purified calcium sulfate pellet at physiologic PH, loaded with Vancomycin and Tobramycin, in the treatment of infected total joints. Paper presented at: Western Orthopaedic Association Annual Meeting. Proceedings of the 75th Annual Meeting of the Western Orthopaedic Association; 2011 Jul 27-30; Honolulu, Hawaii.
24. Maale GE. The use of antibiotic loaded synthesized calcium sulfate pellets in the one stage treatment for Osteomyelitis. Paper presented at: Annual Open Scientific Meeting of the Musculoskeletal Infection Society 2009. Proceedings of the 19th Meeting of the Musculoskeletal Infection Society; 2009 Aug 7-8; San Diego, California.
25. Mackey D, Varlet A, Debeaumont D. Antibiotic loaded plaster of Paris pellets: An in vitro study of a possible method of local antibiotic therapy in bone infection. *Clinical Orthopaedics and Related Research*. 1982; 167: 263-8.
26. McPherson EJ, Peters CL. Musculoskeletal Infection. In: Flynn JM, ed. *Orthopaedic Knowledge Update*. 10th ed. Rosemont, IL: American Academy of Orthopaedic Surgeons; 2011: 239-58.
27. McPherson EJ, Woodson C, Holtom P. Periprosthetic Total Hip Infection: Outcome Using a Staging System. *Clinical Orthopaedics and Related Research*. 2002; 403: 8-15.
28. Miclau T, Dahners LE, Lindsey RW. In vitro pharmacokinetics of antibiotic release from locally implantable materials. *Journal of Orthopaedic Research*. 1993; 11: 5627-32.
29. Mirzayan R, Panossian V, Avedian R, Forrester DM, Menendez LR. The use of calcium sulfate in the treatment of benign bone lesions: a preliminary report. *Journal of Bone and Joint Surgery*. 2001; 83: 355-358.
30. Mousset B, Benoit MA, Delloye C, Bouillet R, Gillard J. Biodegradable implants for potential use in bone infection. An in vitro study of antibiotic-loaded calcium sulfate. *International Orthopaedics*. 1995; 19: 157-61.
31. Nelson CL, Griffin FM, Harrison BH, Cooper RE. In vitro elution characteristics and noncommercially prepared antibiotic PMMA beads. *Clinical Orthopaedics and Related Research*. 1992; 284: 303-9.

32. Nelson CL, Hickman SG, Harrison BH. Elution characteristics of gentamicin-PMMA beads after implantation in humans. *Orthopedics*. 1994; 17: 5415-6.
33. Panagopoulos P, Tsaganos T, Plachouras D et al. In vitro elution of moxifloxacin and fusidic acid by a synthetic crystalline semihydrate form of calcium sulphate (Stimulan™). *International Journal of Antimicrobial Agents*. 2008; 32(6): 485-7.
34. Papagelopoulos PJ, Mavrogenis AF, Tsiodras S et al. Calcium Sulfate delivery system with Tobramycin for the treatment of chronic Calcaneal Osteomyelitis. *The Journal of International Medical Research*. 2006; 34: 704-712.
35. Parker AC, Smith JK, Haggard WO. Evaluation of two sources of Calcium Sulfate for a local drug delivery system: a pilot study. *Clinical Orthopaedics and Related Research*. 2011; 469(11): 3008-15.
36. Patzakis MJ, Mazur K, Wilkins J, et al. Septopal beads and autogenous bone grafting for bone defects in patients with chronic osteomyelitis. *Clinical Orthopaedics and Related Research*. 1993; 295: 112-8.
37. Peltier LF, Bickel EY, Lillo R, et al. The use of plaster of paris to fill defects in bone. *Annals of Surgery*. 1957; 146: 61-69.
38. Pietrzak WS, Ronk R. Calcium sulfate bone void filler: a review and a look ahead. *Journal of Craniofacial Surgery*. 2000; 11(4): 327-333.
39. Pulido L, Ghanem E, Joshi A. Periprosthetic Joint Infection, the incidence, timing, and predisposing factors. *Clinical Orthopaedics and Related Research*. 2008; 466: 1710-15.
40. Robinson D, Alk D, Sandbank J, Farber R, Halperin N. Inflammatory reactions associated with a calcium sulfate bone substitute. *Annals of Transplantation*. 1999; 4(3-4): 91-97.
41. Sulo I. The use of gentamicin impregnated plaster beads in the treatment of bone infections. *Revue de Chirurgie Orthopedique*. 1993; 79: 299-305.
42. Toms AD, Davidson D, Masri MA. The Management of Periprosthetic Infection in Total Joint Arthroplasty. *The Journal of bone and joint surgery*. *British volume*. 2006; 88(2): 149-155.
43. Tunney MM, Anderson N, et al. Detection of Prosthetic Hip Infection at Revision Arthroplasty by Immunofluorescence Microscopy and PCR Amplification of the Bacterial IGS rNA Gene. *Journal of Clinical Microbiology*. 1999; 37(10): 3281-90.
44. Turner TM, Urban RM, Gitelis S, Sumner DR, Haggard WO, Parr JE. Antibiotic delivery from calcium sulfate as a synthetic bone graft in a canine defect. *Transactions of the Annual Meeting - Orthopaedic Research Society*. 1998; 23: 597.
45. Varlet A, Dauchy Ph, Hingrez M. Osteogenetic induction by antibiotic loaded plaster of Paris pellets combined with decalcified bone matrix. *Revue de Chirurgie Orthopedique*. 1985; 71: 73-8.
46. Walenkamp GH, Kleijn LL, de Leeuw M. Osteomyelitis treated with gentamicin-PMMA beads: 100 patients followed for 1-12 years. *Acta Orthopaedica Scandinavica*. 1998; 69: 5518-22.
47. Zimmerli W, Trampuz A, Ochsner PE. Current Concepts, Prosthetic Joint infections (Review Article). *The New England Journal of Medicine*. 2004; 351: 1645-54.



Edward J. McPherson, MD

My Practice
www.laoi.org



My Research Facility
www.jisrf.org



My Medical Center
www.stvincentmedicalcenter.com



As an Orthopaedic surgeon in Los Angeles, CA, I'm grateful to practice medicine in an area with exceptional healthcare. My choice is to practice at St. Vincent Medical Center. My research is in collaboration with JISRF, Founded here in L.A. in 1971 by Prof. Charles O. Bechtol, MD.