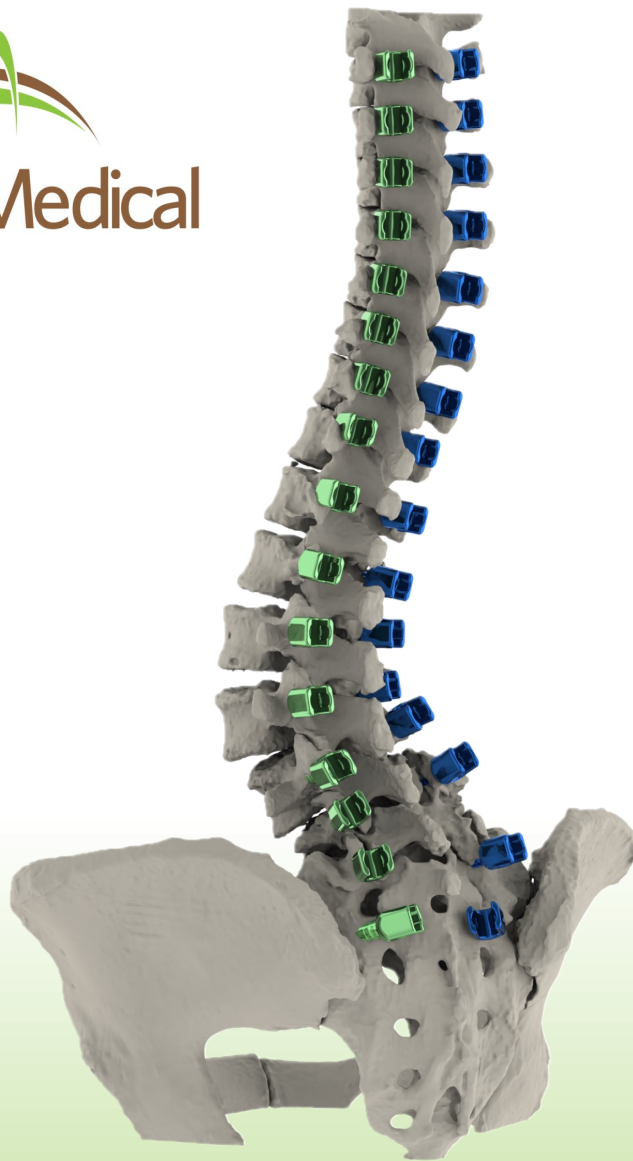

FIREFLY[®] Case Study

Mitigating Risk in Adult Spinal Deformity Surgery for a Jehovah's Witness Patient

Authors

Jean-Christophe Leveque, MD
Rajiv Sethi, MD
Kellen Nold, PA-C

Hospital

Virginia Mason Medical Center - Neurosurgery



Patient History:

- 77 year old / Female
- Primary Diagnosis:
 - Adolescent Idiopathic Scoliosis
 - Adult Degeneration
 - Grade 1 Anterolisthesis of L3/L4, L4/L5 and L5/S1

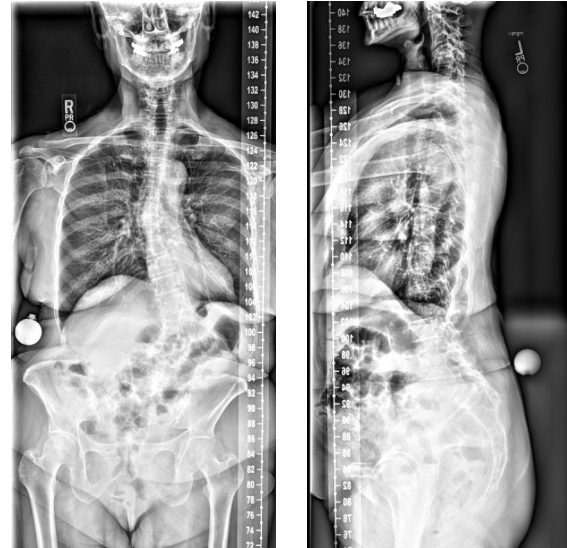
Treatment Plan:

- Stage 1: L4/5 and L5/S1 ALIF
- Stage 2: PSF T4 - S2AI
 - T5 - S2AI utilizing FIREFLY PSG

Pre-Surgical Planning:

This case is a 77 year old female with a history of adolescent idiopathic scoliosis diagnosed at age 14. The patient developed multi-level degenerative spondylosis with grade 1 anterolisthesis from L3 to S1 and had been experiencing progressively worsening back pain over the past 13 years.

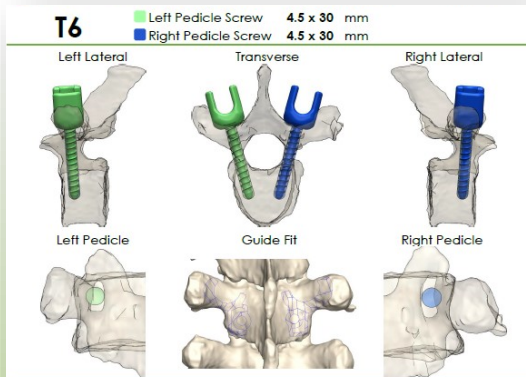
Due to this patient's religious beliefs, receiving a blood transfusion was not an option. To help mitigate the risk caused by blood loss, the procedure was staged across 2 days with anterior lumbar interbody fusion at L4/5 and L5/S1 on day 1 and posterior T4 - pelvis fusion performed on the second day. The posterior portion of the procedure was completed by 2 highly experienced surgeons (1 neuro, 1 ortho) using FIREFLY guides.



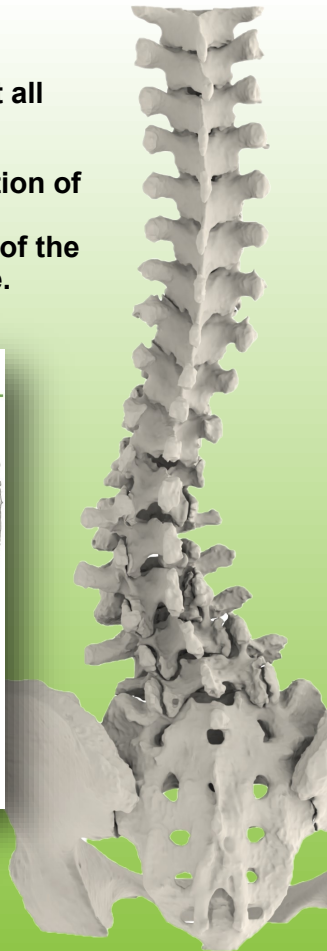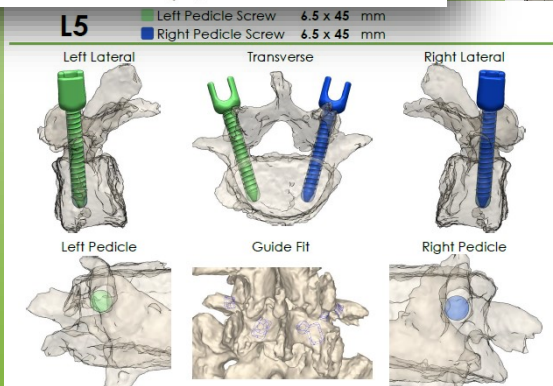
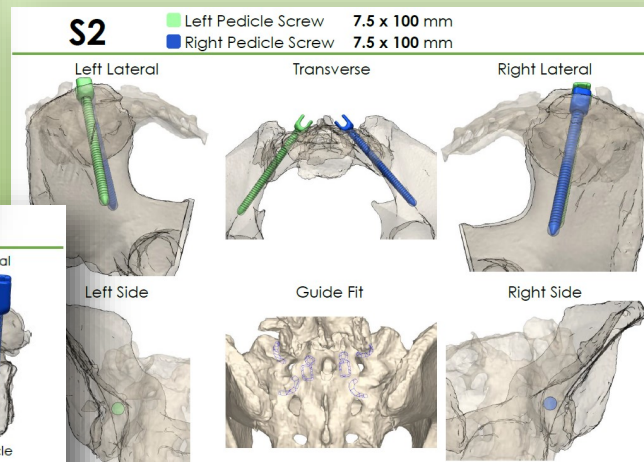
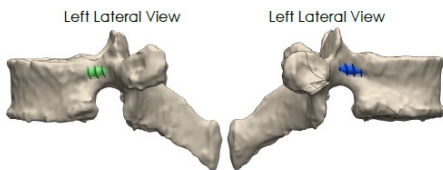
Pre-Operative Imaging

A preoperative CT was utilized to create a 3 dimensional model of the patient's spine with FIREFLY guides used for screw trajectories at all levels from T5 through S2 alar iliac.

The primary goals of surgery were the correction of her coronal and sagittal deformity as well as stabilization of the curve and decompression of the lower lumbar segments in the fractional curve.



Supplemental Information
Due to small pedicle size there is a significant left and right lateral breach.



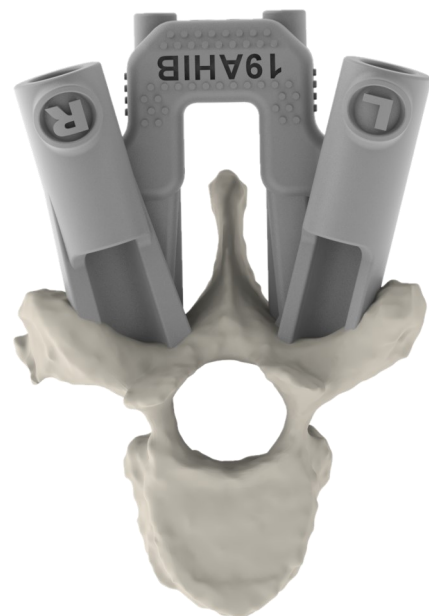
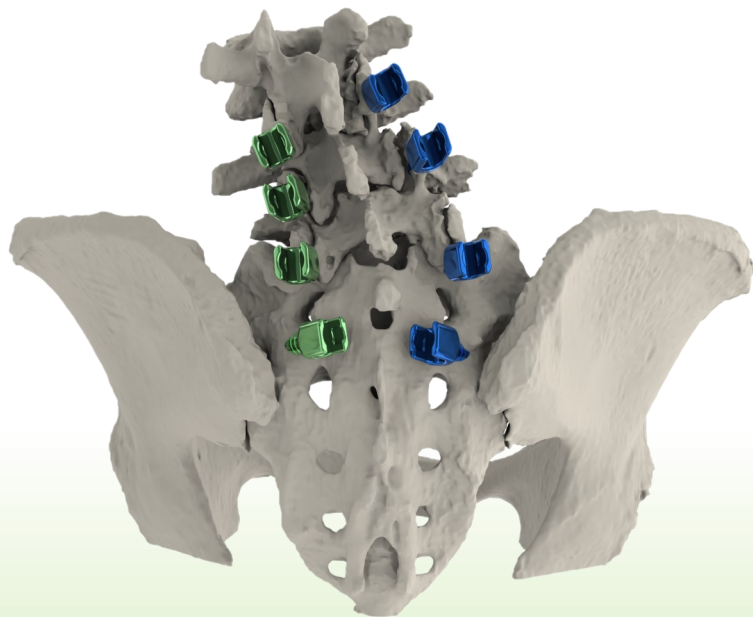
Intra-Operative (Posterior Procedure):

After exposure of the posterior spine, FIREFLY guides were put into position at each level in sequence. A pilot hole was drilled into the pedicle on each side, tapped and then instrumented with the predetermined pedicle screw. Pedicle screws were used from T5 through the pelvis. L1 screws were not put in on either side due to very small pedicles identified in the preoperative plan.

After placement of all screws, their accuracy was confirmed with AP C-arm fluoroscopy. The majority of screws were 4.5-5.5 mm in diameter in the thoracic spine while the lumbar screws were 6.5 mm in diameter. The S2

alar iliac screws measured 9.5 mm in diameter by 90 mm in length and were placed using an S1/S2AI FIREFLY guide. Transverse process hooks were placed at T4.

After arthrodesis a 5.5 cobalt chrome rod was used bilaterally with derotation to correct the deformity. Allograft, autograft harvested from the spinous process of the mid-thoracic and lumbar spine and one large kit of bone morphogenic protein were used to create a bony fusion construct.



Post-Operative Results:

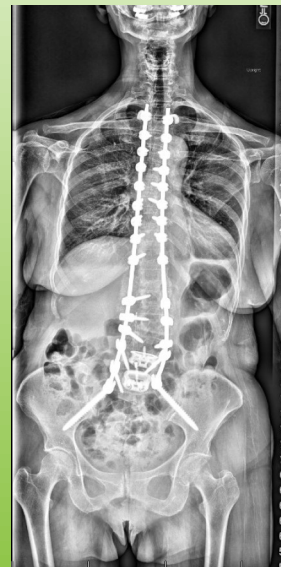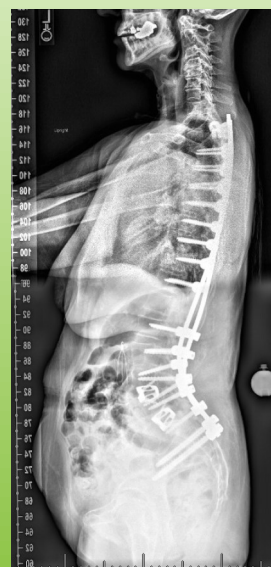FIREFLY guides reduced screw placement time^{1-4,6}. The total operative time was 3 hours and 30 minutes. By using FIREFLY guides, the total instrumentation time for 32 screws was 50 minutes, including the placement of S2AI screws.

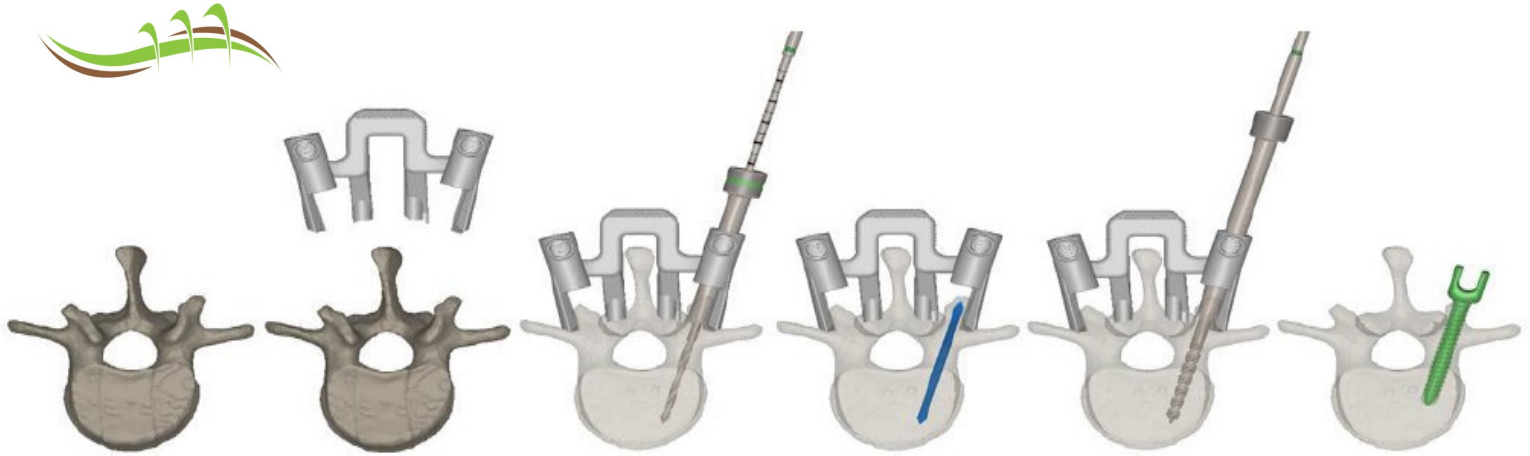
FIREFLY guides minimized the use of intra-operative radiation: A total of 14 seconds of fluoroscopy was used during the procedure⁷.

The reduced OR time contributes to reduced blood loss: The total estimated blood loss during the procedure was 600 cc, while average blood loss of a case this size is typically 3200 cc or greater¹⁻⁴.

There was a substantial improvement in the degree of scoliosis from the preoperative imaging⁶. Specifically, there is a substantial decrease in the prior mid thoracic dextroscoliosis and in the lumbar levoscoliosis. After a 7 day hospital stay, including Stage 1 and 2 of the procedure, the patient was discharged. At the 6 month post operative checkup, the patient stated she was doing very well.

CURVATURE RANGE	PRE-OP DEFORMITY	POST-OP DEFORMITY
Upper Curve	36°	14°
Lower Curve	28°	15°





What is FIREFLY?

Mighty Oak Medical